



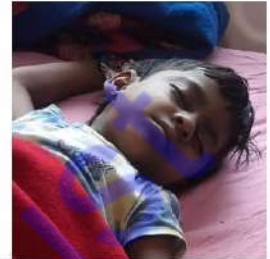CANCER CARE TRUST

Web.add : www.cancercaretrust.org

E.id : contact@cancercaretrust.org

PATIENT APPLICATION FORM

PATIENT'S DETAILS



NAME:	SAMA PARWEEN
FATHER NAME:	MD. TAHIR ALAM
DATE OF BIRTH / AGE:	6 YEARS
SEX:	FEMALE
ADDRESS:	VILL. DARDAHI, NAWADIH, JHARKHAND
DISEASE:	Fanconi Anemia(Blood Cancer)
HOSPITAL DEPARTMENT TREATMENT COST	AIIMS MEDICAL ONCOLOGY Rs. 3,00,000/-

For CANCER CARE TRUST


Authorized Signatory



Parent's Sign

Patient's Blood Group:
 Patient's Name: MISS SAMIA PARWEEN
 Patient ID: 202-R16517
 Hospital: ALIMS Hospital / Dr. A.P.S.
 Date: 11/04/2022

अखिल भारतीय आयुर्विज्ञान संस्थान, नई दिल्ली-110029
 ALL INDIA INSTITUTE OF MEDICAL SCIENCES, NEW DELHI -110029
 आपातकालीन विभाग

(REVISIT)
 UHID No:105736062
 समय TIME: 05:07:22 AM
 NON-MLC

(DEPT. OF EMERGENCY MEDICINE)
 दिनांक DATE: 11/04/2022
 नं. (Emergency No): 2022/030/0026543

नाम NAME: MISS SAMIA PARWEEN
 आयु AGE: 6 years 3 months 25 days
 लिंग/SEX: F
 D/O: MD TAHIR ALAM
 पता ADDRESS: मकान संख्या H.NO: VILL DARDAHI NAWADIH DARDAHI
 शहर/प्रखंड CITY/BLOCK: JHARKHAND
 राज्य STATE:
 गली/मुहल्ला STREET/MOH: 0
 पिन PIN:
 स्थान Location: Paediatrics Emergency
 Criticality: Red / Yellow / Green

द्वारा BROUGHT BY: Police FATHER

Triage:	Responsive/Unresponsive	HR	/min	BP	mmHg	RR	/min	spO2	%
Shifted to Paeds/ Main/ New Emergencies									
Presenting Complaints	<p> <i>Kfp</i> <u>Fanconi Anemia</u> = FN → throat pain since night → Headache on the back of head since night → Bluish spots all over body x 2 days → Fever on/off x 3 days - low grade (undocumented) bleeding from any site </p>								
Primary Assessment (ABCDE):	<p> Airway: <u>No</u> <i>no</i> <u>wheezing</u> / abnormal movements / <u>from any site</u> Circulation: <u>HR 116</u> /min - <u>deaf</u> <u>causely</u> <u>Haemorrhages</u> 15/15 <u>CFT 12</u> sec. - <u>over Rt</u> <u>tonsillar</u> <u>area</u> ⊕ <u>BP 110/70</u> mmHg Peripheral pulse: <u>Poor</u> / <u>Good</u> Central pulse: <u>Poor</u> / <u>Good</u> Skin temp: <u>Warm</u> / <u>cool</u> Others: <u>P/A - left BSA</u> <u>NO OR</u> </p>								
Disability	<p> Pupil size: <u>15/15</u> /min Pupillary Reactions: <u>Deviation</u> <u>of face to</u> <u>ltside</u> Motor activity: <u>Normal & Symmetrical/Asymmetrical/Posturing/Flacidity/Seizure</u> Blood Sugar:mg/dl Exposure: <u>97</u> <u>80F</u> Temp: Colour: <u>Normal</u> / <u>pallor</u> / <u>cyanosis</u> / mottled Any other skin lesions: </p>								
Added sounds:	<p> None / Stridor/Wheeze/Crackles SpO2 on Room air: <u>98%</u> <u>URA</u> CUS → <u>S₁S₂ ⊕</u> <u>No</u> </p>								

Diagnosis: *Kfp* Fanconi Anemia / FN / ? at line Att-160
 ? IC bleed
 facial nerve palsy
 Plan: urgently arrange 40 RDP
 CBC/URU / Bleeds → Bottle N.A.

अखिल भारतीय आयुर्विज्ञान संस्थान, नई दिल्ली-110029
ALL INDIA INSTITUTE OF MEDICAL SCIENCES, NEW DELHI-110029

नाम Name: Sarma Bhowan
उम्र Age: 60y/F
सर्विस Service: [blank]
दिनांक Date: [blank]
यू.एच.आई.डी. नं. UHID No. 105736002
प्रोफेसर इंचार्ज Professor I/C: Prof. S. Gualati / Dr. B. Chhabra / Dr. P. Jaisi
Notes written by: Dr. Ashish

CLINICAL NOTES

L/S/B Pachymeningeal SD skull

F/L/L/O Falcine Aneurysm - FN

C/O fever & throat pain
on & off headache

& mild deviation of angle of mouth to Right

No C/O vomiting / LOC / double vision

No other focal neurological deficits

O/E child irritable but consolable

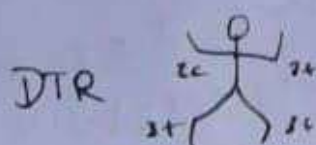
Petechial spots (+)

Mucosal ulcers (+)

Mild ~~swell~~ of Nasolabial fold in (L) side

Plantar withdrawal

Power $\frac{2/5}{2/5}$ / $\frac{2/5}{2/5}$ Tone (N)



No Menigeal signs

अखिल भारतीय आयुर्विज्ञान संस्थान, नई दिल्ली-110029
ALL INDIA INSTITUTE OF MEDICAL SCIENCES, NEW DELHI-110029

नाम Name: Same Parashar
उम्र Age: 61/7
सर्विस Service: [Blank]
दिनांक Date: [Blank]
यू.एच.आई.डी. नं. UHID No.: 105736062
Notes written by: R. Negi

CLINICAL NOTES

27

(S) B SR 2 + 14 mm R Negi
No FA on random
Fever since 5/4/22 was associated
Cough, dry
steroid on piperaz, Amikacin, Meloxyl
presented with headache
gen bleed
↓
causal (K) frontal paranasal 2
subacute suppurative lesion → ? (Gly)
14 C hemogram
WBC < 100 per cent 2
eye pain comm on
pallon ⊕ No 2 (g) (dubly)
CNE ⊕
PR - 116/m BN - 110/70 AN - 20/27
SpO₂ - 98%

अखिल भारतीय आयुर्विज्ञान संस्थान, नई दिल्ली-110029
 ALL INDIA INSTITUTE OF MEDICAL SCIENCES, NEW DELHI-110029

Ms. Samra Parween Age 64r Sex F

वैवाहिक स्थिति
Marital Status

यू.एच.आई.डी. नं.
UHID No.

105736082

सेवा
Service

वार्ड
Ward

बेड
Bed

व्यवसाय
Occupation

धर्म
Religion

ALL INJECTIONS TO BE INITIALED BY PERSON ADMINISTERING

Date & Time	Medication & Treatment	Diet	Observation by the Nurse
11pm	inj. Zosyn 1.6gm iv TDS		
	inj. Amikacine 240mg iv O.D		
11pm	inj. Metrogyl 160mg iv TDS		
	inj. Pcm 200mg iv S.O.S		

Cancer Care Trust

अखिल भारतीय आयुर्विज्ञान संस्थान, नई दिल्ली-110029
ALL INDIA INSTITUTE OF MEDICAL SCIENCES, NEW DELHI-110029

नाम Name: Sania Kaveen उम्र Age: 6y लिंग Sex: F वैवाहिक स्थिति Marital Status: वृ.एच.आई.डी. नं. UHID No.
सेवा Service: वार्ड Ward: बेड Bed: व्यवसाय Occupation: धर्म Religion:

ALL INJECTIONS TO BE INITIALED BY PERSON ADMINISTERING

Date & Time	Medication & Treatment	Diet	Observation by the Nurse
<u>11/4/22</u>	<p><u>11:50 pm</u> <u>Abcort</u> <u>HR = 104/min</u> <u>RR = 22/min</u></p> <p><u>discussed with SR, referred to any other Govt. hospital of beds. Child requires admission on NCT ? IC bleed/infection ? NCC (without edema) for evaluation of the same.</u></p> <p><u>7 RDP transfused</u></p> <p><u>On Inj. Zoxo, Amikacin, Metronidazole, Inj Pantop, Emul, Inj Tranexa 2500 IV TDS, Tab Leuva 500mg 1 - 1/2 PO BD</u></p>	<p><u>CR1 & 3s</u> <u>Peripheries warm</u></p> <p><u>Haematology</u></p>	<p><u>case has been referred to RML/CNBC/GB part</u></p> <p><u>non-availability of hypodermic lesion</u></p> <p><u>frontal, parasagittal & subcortical hypodermic lesion</u></p> <p><u>to continue</u></p>